

Placement of Dental Implant in a Knife Edge Ridge in Anterior Aesthetic Zone

NARPAT SINGH RAJPUT¹, J. BHASKAR², MOHAN VALIATHAN³, S.C. CHANDRASEKARAN⁴, MD. NAZISH ALAM⁵

ABSTRACT

Dental implants are established alternatives for replacing missing teeth. Dental implants are artificial tooth root, positioned in the jaw bone, in order to sustain the replacement tooth or bridge. Recent advance in dental implant technology has made it more convenient, efficient and affordable for patients. In the anterior maxilla, esthetic demands not only require well-anchored implants but also sufficient soft and hard tissue in order to achieve natural looking result. Augmentation of the resorbed alveolar crest can be achieved, for example, with onlay bone grafts, membrane techniques, bone distraction and bone splitting. This report highlights the placement of implants in compromised alveolar ridges with good results. Implant was successfully restored and follow-up done for one year.

CASE REPORT

A 49-year-old male patient presented to the Department of Periodontics at Shree Balaji Dental College And Hospital, Chennai, India, for management of partially edentulous area in lower anterior region in relation to tooth no. 31,32,41,42. After clinical and radiographic evaluation, OPG revealed a crestal bone loss in posterior teeth and missing 31,32,41,42 [Table/Fig-1]. Bony architecture in CT Scan showed knife edge bone in crestal region. The patient was given the option of dental implant versus crown & bridge, he opted for the former.

After induction of local anaesthesia, an incision was given and a full thickness flap was elevated [Table/Fig-2 and 3]. Due to deficient bone, osteotomy was initiated using a sharp pilot D-shaped expander followed by condensation of the osteotomy site using bone condensers. Following the osteotomy dental implant of size 3.3 x 11.5 mm was placed achieving primary stability. On the facial aspect osseograft and PRF was placed for augmentation of deficient region and sutured using vicryl sutures. Post operative instructions and medications were prescribed for five days and the patient was reviewed after 24 hours. Every month clinical follow up was done along with intraoral periapical radiographs. The implant was perfectly osseointegrated within the confines of the bone with in a period of 3 months following which second stage surgery was performed for healing abutment placement. Final prosthesis was placed and reviewed clinically with radiographic evaluation every 3 months for a 1-year period. Excellent aesthetics was achieved [Table/Fig-4-9].

DISCUSSION

Dental implants work by a process known as Osseointegration. Swedish researcher, Per-Ingvar Branemark described the concept of "osseointegration" as "a direct, structural and functional connection between ordered, living bone and the surface of a load-carrying implant" after discovering the complete integration of rabbit bone with the implant. Thereafter, he successfully began experimenting titanium implant on humans in 1960's [1,2]. Implants osseointegration for the rehabilitation of partial or complete edentulism is generally considered as the method of choice if there are no local or systemic contraindications [3]. For dental implant procedure to work, there must be enough bone in the jaw, and the bone has to be strong enough to hold and support the implant. In all cases, careful consideration must be given to the final functional aspects of the restoration, such as, assessing the forces which will be placed on the implant. First, the dentist must determine what

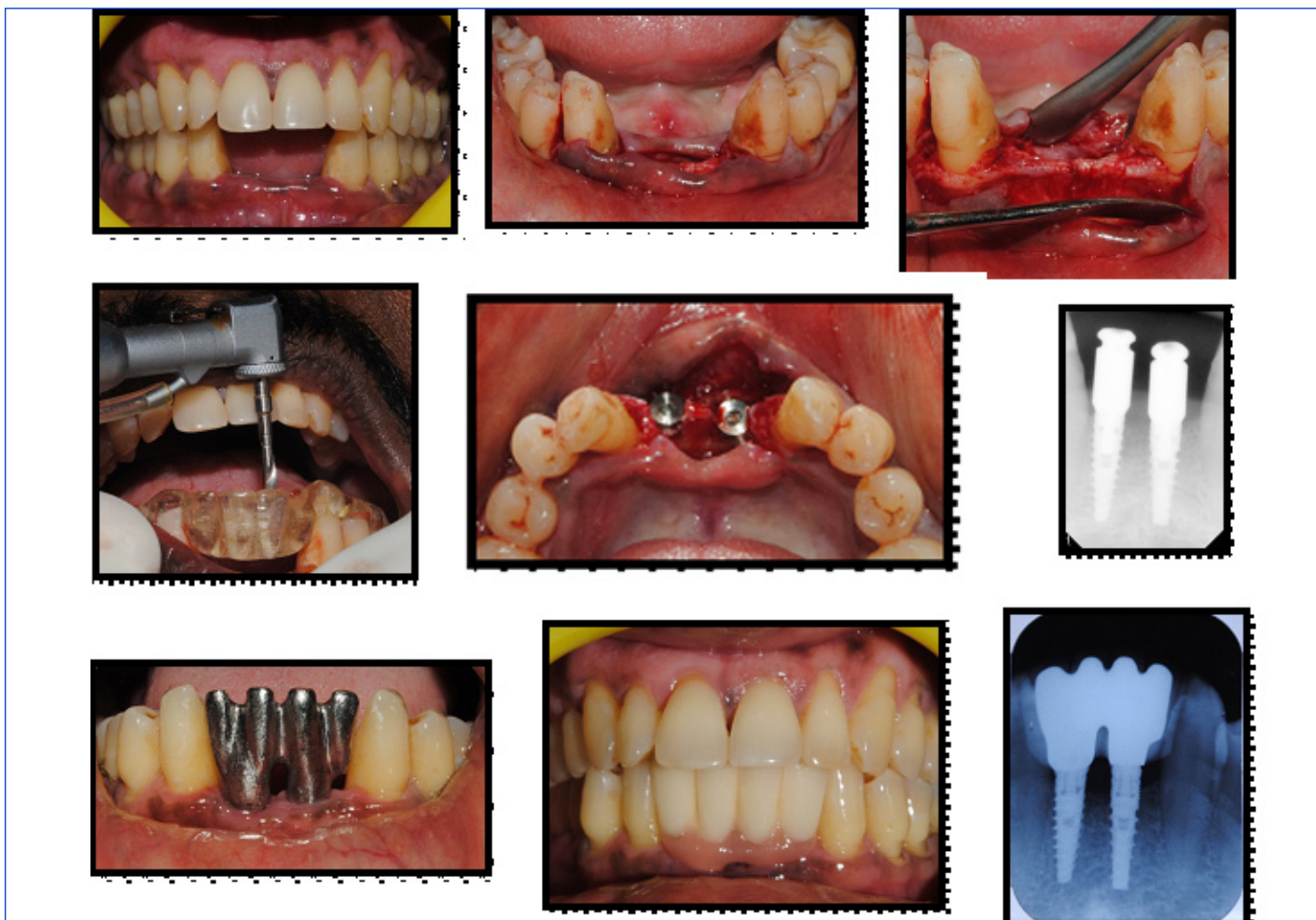
Key words: Osteotomes, Platelet-Rich Fibrin, Dental Implants

type of prosthesis will be fabricated. Only then, can the specific implant requirements including number, length, diameter, and thread pattern be determined. Dental implant success is related to operator skill, quality and quantity of the bone available at the site and the patient's oral hygiene. Ill-fitting prosthesis may cause mechanical failures of the prosthesis, implant systems, or biologic complications of the surrounding tissue. The success of prosthesis depends on how well it fits without causing injury to the remaining teeth and soft tissues [4].

Thorough evaluation of edentulous site, in the aesthetic zone must be done for implant placement. Garber has proposed a classification for such sites depending on the type of reconstruction needed to get good positioning of the implant [5,6]. Replacement of multiple missing teeth in the aesthetic zone is challenging particularly when the three dimensional architecture of the existing bone and soft tissue is deficient. The bony housing in this instance, would require augmentation to provide a configuration that permits placement of implants in optimal positions which in turn would result in pleasing aesthetics [7]. Predictably, consistency and success rate of implant is maximum in anterior mandibular area [8,9].

When the teeth are absent, the alveolar bone slowly resorbs, leading to ridge deformities. A sharp bony ridge is a frequent problem among the edentulous patients and commonly occur in the mandible in the edentulous patient [10]. Al-Faleh W, reported that 46.5% proposed implant sites had knife edge configuration [3]. Patient in current case also had knife edge ridge in anterior aesthetic zone. Here, condensation of the osteotomy site using bone condensers was used. Study by Padmanabhan and Gupta concluded that the osteotome technique is good for the knife-edge ridges as claimed earlier that using bone condensing to prepare the implant site in soft maxillary bone avoids the risk of heat generation, and implants can be placed precisely with increased primary stability [11].

In the given case, the implant was perfectly osseointegrated and excellent aesthetics was achieved. Singh M et al., too reported a similar case, in a 60-year-old male patient where missing 31,32, 41,42,43 was placed with three double-staged implants of 3.3 mm diameter and 15 mm length for 31. A 3.3 mm diameter and 13 mm length for 41 and 42, two natural teeth each on distal side of edentulous region, were prepared (44 and 33). Patient reported high satisfaction for oral function, esthetics, speech and prosthesis adaptation [12]. In a study, Hof M et al., noticed high subjective patient satisfaction with implant esthetics in the partially edentulous anterior mandible (87%) [13].



[Table/Fig-1]: Preoperative view of missing teeth, **[Table/Fig-2]:** Incision of flap, **[Table/Fig-3]:** Elevation of flap, **[Table/Fig-4]:** Placement of Surgical Stent and Drilling Sequence **[Table/Fig-5]:** Placement of implant, **[Table/Fig-6]:** (With Transfer Coping), **[Table/Fig-7]:** Intra-operative photos, **[Table/Fig-8]:** Metal Try-in **[Table/Fig-9]:** Post-op Photos

CONCLUSION

Multiple factors work for successful implant osseointegration. However, with careful implant-prosthetic treatment planning, high satisfaction for oral function, esthetics, speech and prosthesis adaptation can be achieved. Implants in anterior mandibular area is considered to be most predictable, stable, with high success rate and patients' satisfaction with implant esthetics.

REFERENCES

- [1] Brånemark PI. Vital microscopy of bone marrow in rabbit. *Scand J Clin Lab Invest.* 1959;11(Suppl.38):1-82.
- [2] Brånemark PI. Osseointegration and its experimental studies. *J Prosthet Dent.* 1983;50:399-410.
- [3] Al-Faleh W. A radiographic study on the prevalence of knife-edge residual alveolar ridge at proposed dental implant sites. *Saudi Dental Journal.* (2009);21(1): 23-27.
- [4] Shetty MS and Shenoy KK. Techniques for Evaluating the Fit of Removable and Fixed Prosthesis. *ISRN Dent.* 2011; 2011: 348-72.
- [5] Al-Sabbagh M. Implants in the Esthetic Zone. *N Am.* (2006): 50: 391-407.
- [6] Garber DA, Rosenberg ES. The edentulous ridge in fixed prosthodontics. *Compend Contin Educ Dent.* 1981;2(4):212-23.
- [7] Jivraj S & Chee W. Treatment planning of implants in the aesthetic zone. *British Dental Journal* 201, 77 - 89 (2006).
- [8] Drago CJ. Rates of osseointegration of dental implants with regard to anatomical location. *J Prosthodont.* 1992 Sep;1(1):29-31.
- [9] Tolstunov L. Implant zones of the jaws: implant location and related success rate. (2007): 33(4): 211-20.
- [10] Katna V, Chopra V, Chadda AS, Gaur A. Management Of Knife Edge Ridge- A Case Report. *Indian Journal of Dental Sciences:* 2011: 3(5): 57-58.
- [11] Padmanabhan TV, Gupta RK. Comparison of crestal bone loss and implant stability among the implants placed with conventional procedure and using osteotome technique: a clinical study. *J Oral Implantol.* 2010;36(6):475-83.
- [12] Singh M, Singh A, Rajpal J, Gupta K K, Singh V. Rehabilitation of mandibular fracture with anterior teeth loss. *Natl J Maxillofac Surg.* 2011;2:63-5.
- [13] Hof M, Tepper G, Koller B, Krainhöfner M, Watzek G, Pommer B. Esthetic evaluation of single-tooth implants in the anterior mandible. *Clin Oral Implants Res.* 2013 Jun 17. doi: 10.1111/clr.12210. [Epub ahead of print].

PARTICULARS OF CONTRIBUTORS:

1. Post Graduate, Department of Dentistry, Shree Balaji Dental College and Hospital, Chennai, India.
2. Professor, Department of Dentistry, Shree Balaji Dental College and Hospital, Chennai, India.
3. Professor, Department of Dentistry, Shree Balaji Dental College and Hospital, Chennai, India.
4. Head of the Department, Sree Balaji Dental College and Hospital, Chennai, India.
5. Assistant Professor, Department of Dentistry, Shree Balaji Dental College and Hospital, Chennai, India.

NAME, ADDRESS, E-MAIL ID OF THE CORRESPONDING AUTHOR:

Dr. Md. Nazish Alam,
Assistant Professor, Department of Periodontology, Shree Balaji Dental College and Hospital,
Velacherry Main Road Pallikarnai, Chennai 600100, India.
Phone: 9884325366, E-mail: dr.naz.ish.alam@gmail.com

FINANCIAL OR OTHER COMPETING INTERESTS: None.

Date of Submission: Dec 01, 2012
Date of Peer Review: Feb 11, 2013
Date of Acceptance: Jun 21, 2013
Date of Publishing: Oct 05, 2013